

A STUDY ON GROSS ANATOMY OF EQUINE TEETH AND VALUES OF DIFFERENT MACROSCOPIC CHARACTERISTICS OF INCISOR TEETH ON AGING THE HORSE

Servet KILIÇ¹ Peddy M. DIXON² Sait BULUT¹ Mustafa KÖM¹

Firat University, Veterinary Faculty, Department of Surgery, Elazığ-Türkiye
University of Edinburgh, Veterinary Field Station, Easter Bush, Roslin, Scotland

At Dişlerinin Anatomisi Ve Keseci (İnsisiv) Dişlerin Değişik Makroskopik Özellikleri Ile Yaş Tayininin Güvenilirliği Üzerine Bir Çalışma

ÖZET

Bu çalışmada atların insisiv, kanin, premolar ve molar dişlerin makroskopik özellikleri ve fonksiyonları gözden geçirildi. Süt dişlerin çıkış ve dökülme süreleri, kalıcı dişlerin çıkış süreleri ve aşınmaya bağlı olarak insisiv dişlerde meydana gelen makroskopik değişiklikler detaylı olarak incelendi. Böylece, bu özelliklerin atlarda yaş tayininde kullanılmasının güvenilirliği son zamanlarda bu alanda yayınlanan bilimsel çalışmaların ışığı altında tartışıldı. Ayrıca, yazarlar 38 atın dişleri üzerinde yaptıkları çeşitli makroskopik incelemelerden elde ettikleri sonuçları ilgili konular içerisinde belirtmişlerdir.

Anahtar Kelimeler: At, Diş, Anatomi, İnsisiv, Yaş

SUMMARY

The present study reviewed gross anatomic features and functions of incisor, canine, premolar and molar teeth of horses. Eruption and shedding times of deciduous, eruption times of permanent teeth, and development of various wear related macroscopic features on incisor teeth have been evaluated in detail. Thus, the reliability of these features to estimate a horse age is discussed under the light of recently published paper on this particular area. In addition, the present authors have noted the results of their examinations on the different macroscopic features of the teeth of 38 horses in related subjects.

Keywords: Horse, Teeth, Anatomy, Incisor, Age

INTRODUCTION

Equine mouth accommodates certain numbers of teeth to carry out some functions including prehension and preparation of the food for digestion (15, 24). These functions requires normal alignment of individual tooth and dental arcade, healthy dental structure and its related supporting structures. It is highly important for a referral surgeon to have comprehensive knowledge about the normal structures of the teeth in order to determine dental related disorders. In addition to the function of teeth in digestion, the equine incisors have a long history of being used for aging the horse (15). However, some critical studies (22, 23, 27) have recently risen a question on the value of traditional aging methods. Therefore, the present paper will review the gross anatomy, eruption and shedding times of the

deciduous and permanent teeth and various wear characteristic of incisor teeth in detail, and discuss the problem of the reliability of these characteristics regarding to estimating the horse's age.

Dental functions

Adult equine mouths have four types of teeth, termed incisors, canines, premolars and molars, in a rostro-caudal order. Each type the of tooth has certain morphological characteristics and specific functions which include the prehension and preparation of food for digestion. Incisor teeth are specialised for the prehension and cutting of food. The canine teeth are for defense, for capture of prey by carnivores, and are used for excavation by animal with tusks. The check

teeth function as grinders for mastication (15, 24). In addition, teeth are used for grooming and serve in sexual dimorphism and mate selection (1, 15). The horse is equipped with an efficient dental apparatus for grazing and grinding food. Their prolonged

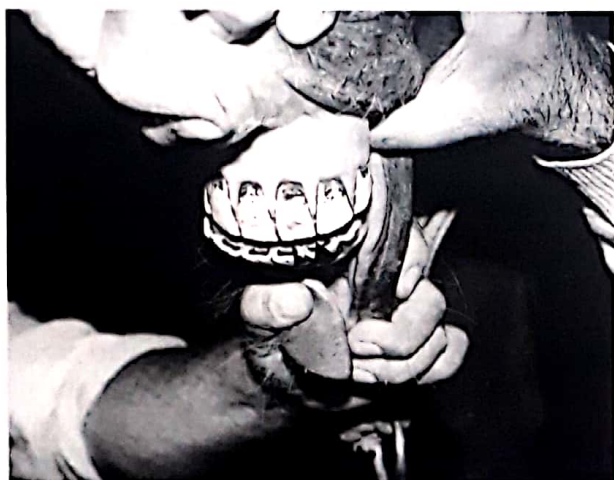

Figure 1. A photograph of 12 y.o. TB stallion shows that the lower dental arcade is in semicircular appearance and that the teeth forming the arcade have well-formed enamel spots (big arrow head) and secondary dentine (small arrow head) on their occlusal surfaces. In addition, the shapes of the occlusal surface (table) of individual teeth are nearly elliptical.

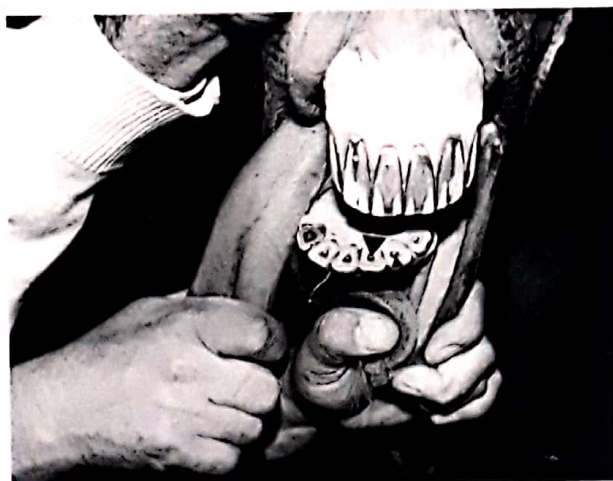

Fig 2: A photograph of 24 y.o. mare TB horses shows that the lower dental arcade is less semicircular (more shallow) than that of previous photograph and all teeth forming the arcade contain the enamel spots (big arrow head) and the secondary dentine (small arrow head) on their occlusal surface. The occlusal surfaces (table) of individual teeth are almost

eruption and high crown characteristics compensate for the high rate of wear, maintaining an efficient dental arcade throughout the horse life.

triangular in shape.

Equine dental formula

The horse is diphyodonts, i.e. have two sets of teeth, termed temporary (deciduous, primary or milk) and permanent (secondary) teeth (24). In foals the deciduous teeth which consist of incisors and premolars are erupted at birth or erupt shortly afterwards. The deciduous teeth are replaced by the larger permanent teeth, but in the horse the transverse area of the deciduous cheek teeth is similar to that of the adult, in contrast to brachyodont teeth (9). Macroscopically, deciduous incisors are whiter and contain wider and shallower infundibula than their permanent successors, which usually erupt on their lingual aspect. The dental formula of deciduous and permanent teeth in horses are:

Deciduous teeth: $2 (D_i \frac{3}{3}, D_c \frac{0}{0}, D_m \frac{3}{3}) = 24$

Permanent teeth: $2 (I \frac{3}{3}, C \frac{1}{1}, PM \frac{3}{3} \text{ or } \frac{4}{3}, M \frac{3}{3}) = 40 \text{ or } 42$ (23).

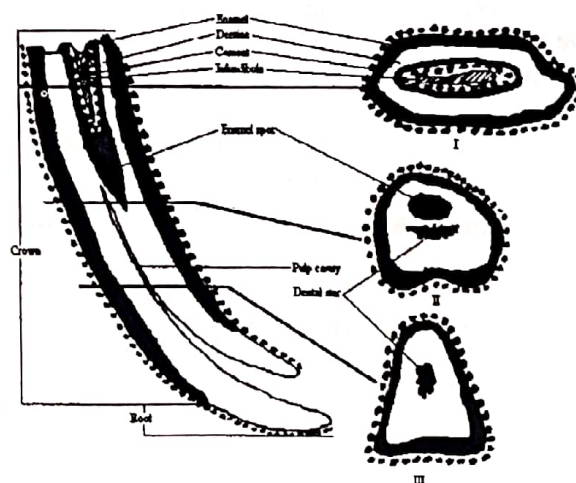


Figure 3. This diagram shows the various anatomical regions of the equine incisor tooth on vertical section, changes of the shape of its occlusal surface and formation of some macroscopic features with wear.

Incisors

Horses have 12 incisors in total, 6 in each arcade which are termed central, intermediate (middle) and corner incisors and are shown

numerically as I1(first), I2 (second), I3 (third). The upper incisor teeth are embedded in the incisive (premaxilla) bone and the lower incisors in the rostral mandible. Eruption and shedding times of the deciduous teeth and eruption times of their permanent successors taken from several different sources are seen in table 1 which shows the presence of a non-significant difference between results. Several critical studies (22, 23, 27) published recently on estimating the horse's age show that the eruption of deciduous and permanent teeth can be used to estimate the age of horses up to 5 years old with a reasonable degree of accuracy.

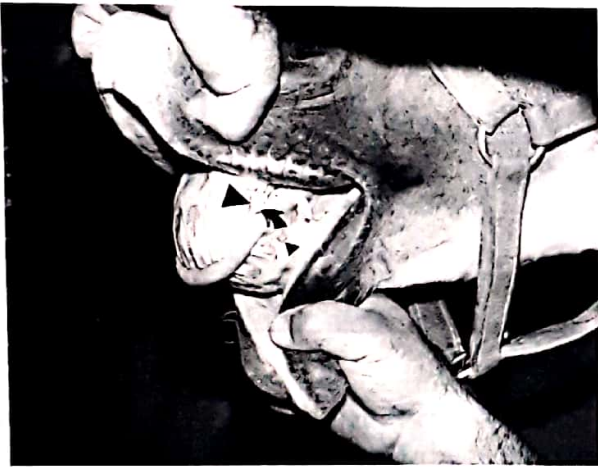


Figure 4. This photograph taken from the lateral view of the upper and lower incisor dental arcades of 13 y.o. TB stallion shows the presence of the hook (arrow) on the upper corner incisor. Galveyne groove (big arrow head) extends half way down to the length of clinical crown of the upper corner incisors. Canine teeth and two extra rudimentary incisors (small arrow head) are present. The angle between upper and lower dental arcades is narrow.

Incisor teeth are curved convexly on their labial aspect and uniformly taper in from the occlusal surface toward the apex. A fully developed incisor arcade in a young adult horse has an almost semicircular appearance, which gradually becomes more shallow with age due to alteration of teeth shape caused by progressive wear (figs 1 and 2) (3, 24).

In addition to their eruption times, equine incisor teeth contain certain macroscopic features that are related to wear, which have also been traditionally utilised for estimating age (13). These structures are the incisal cup (cup), enamel spot (mark), dental star, hooks, presence and size of Galveyne's groove on the upper corner incisors, the occlusal angle between the upper and lower incisors and the shape of the occlusal surface of lower incisors (figs 3 and 4). Disappearance of the cup and enamel spot and appearance times, shape and location of the dental star with wear are shown in tables 2 and 3, respectively. In this regard, the disappearance of the cup, the occlusal angle between the upper and lower incisors, the shape of occlusal surfaces of lower incisors, and Galveyne's groove are considered as relatively reliable indicators of age whilst the disappearance of the mark and the presence of a notch in the caudal upper incisor are unreliable features of age (22, 27). Variations in incisal teeth appearance can also be due to individual variation, environmental conditions, eruption times, mineralisation rates, depth of enamel infundibulum, amount of infundibular cement and the presence of certain stereotypic behaviours such as crib-biting and windsucking (11, 21, 22).

Shape of the incisor occlusal surface

The occlusal surface of incisors are elliptical in recently erupted incisors, but with wear, they successively become round, triangular and then oval in shape (fig 3). These changes are more apparent in the central (I1) and intermediate (I2) than in the corner (I3) incisors (22, 24). The variation of the shape of the occlusal surface of equine incisors with wear can be seen in table 4.

Table 1. Reported eruption times of temporary and permanent equine incisors by different sources. (AAEP: American Association of Equine Practitioners; I1, 2, 3: Incisors 1, 2, 3)

| Sources of Information | Temporary Incisors | | | Permanent Incisors | | |
|-------------------------------|--------------------|-------------|-------------|--------------------|--------------|------------|
| | I1 (days) | I2 (weeks) | I3 (months) | I1 (years) | I3 (years) | I3 (years) |
| Miller and Robertson (1952) | 0-7 | 2-4 | 7-9 | 2.5 | 3.5 | 4.5 |
| Goody (1983) | 0-7 | 4-12 | 8-9 | 2.5 | 3.5 | 4.5 |
| McMullan (1983) | 1-8 | 4-8 | 6-9 | 2.5 | 3.5 | 4.5 |
| Baker (1985) | 0-7 | 4-6 | 6-9 | 2.5 | 3.5 | 4.5 |
| Eisenmenger and Zetner (1985) | 0-a few | 3-8 | 5-9 | 2.5-3 | 3.5 | 4.5 |
| Beeman (1987) | 0-7 | 4-6 | 6-9 | 2.5 | 3.5 | 4.5 |
| Dyce et al (1987) | 6 | 6 | 6 | 2.5-3 | 3.5-4 | 4.5 |
| AAEP (1988) | 0-7 | 4-6 | 6-9 | 2.5 | 3.5 | 4.5 |
| Mueller (1991) | 0-7 | 4-6 | 6-9 | 2.5 | 3.5 | 4.5 |
| Richardson et al (1994) | - | - | - | 2.5 | 3.5 | 4.5 |
| Ranges | 0-8 | 3-12 | 5-9 | 2.5-3 | 3.5-4 | 4.5 |

Table 2. Reported horse ages for the disappearance of the cup and enamel ring in the lower incisors by different studies. (AAEP: American Association of Equine Practitioners; I1, 2, 3: Incisors 1, 2, 3)

| Sources of Information | Worn-out-ages | | | Worn-out-ages | | |
|-------------------------------|---------------|-------------|--------------|---------------------|--------------|--------------|
| | of the cups | | | of the enamel rings | | |
| | I1 (days) | I2 (weeks) | 7-9 (months) | I1 (years) | I3 (years) | I3 (years) |
| Galvayne (1912) | 7 | 8 | 9 | - | - | - |
| Miller and Robertson (1952) | 7 | 8 | 9 | 12 | 13 | 13 |
| DeLahunt and Habel (1965) | 6 | 7 | 8 | 13 | - | 16 |
| Tutt (1968) | 6 | 7 | 8 | - | - | - |
| Goody (1983) | 7 | 8 | 9 | 12 | 15 | 15 |
| McMullan (1983) | 7 | 8 | 9 | ?15 | ?15 | ?15 |
| Baker (1985) | 6 | 7 | 8 | 12 | 13 | 15 |
| Eisenmenger and Zetner (1985) | 6 | 7 | 8 | - | - | - |
| Dyce et al (1987) | 6 | 7 | 8 | 13 | - | 16 |
| AAEP (1988) | 7 | 7 | 8 | 12 | 13 | 13 |
| Mueller (1991) | 7 | 8 | 9 | 12 | 13 | 15 |
| Richardson et al (1994) | 6-7 | 7 | 7-8 | - | - | - |
| Range | 6-7 | 7-10 | 7-10 | 12-15 | 13-15 | 13-16 |

The Incisal cup

The infundibulum present in incisor teeth is termed the incisal cup. This funnel like structure is almost circular in shape and circa 10 mm deep when the tooth first erupts. This infundibulum is usually incompletely filled with cement and consequently become filled with decomposing food material and therefore looks dark (12, 27) claimed that in the mandibular arcade, the cups disappear by 6 years of age in central, 7 years in intermediate and 8 years in the corner incisors. The results of various studies seen in table 2 show marked differences between them. However, critical studies including those of Walmsley (27) and Richardson et al (22) have shown that cups may disappear 1 or 2 years earlier than traditionally expected.

Enamel spot

When the infundibulum is worn away, it leaves behind a small, ring of infundibular enamel located on the lingual aspect of the tooth which is called the enamel spot (enamel ring or mark) (fig 3) (3, 27). Due to the slower wear of enamel as compared to dentine, the enamel spot is elevated above the occlusal surface (fig 5). Many authors including Goody (13), Dyce et al (10) and Mueller (21) stated that the enamel spot disappears by 15 years of age (table 2). However, Richardson et al (22) found these structures absent in a 9 year old horse, yet present in a 20 year old horse.

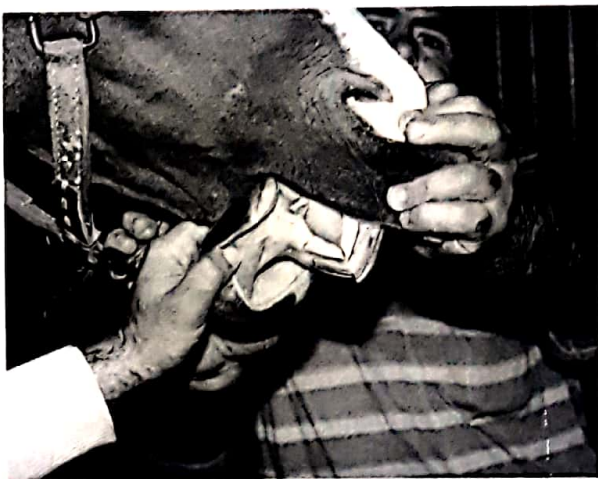

Fig 5: A photograph of 17 y.o. TB stallion shows that the angle between the upper and lower incisor dental arcades is much narrower than that between the upper and lower incisor dental arcades of the previous photograph (fig 4).

Dental star

The dental star represents exposure of secondary dentine within a former pulp cavity on the occlusal surface of incisor teeth. It appears sequentially in the central, middle and corner incisors between 6-14 years of age. It first appears as a dark yellow transverse line (fig 5) on the labial aspect of the cup, then with further tooth wear it gradually becomes oval in shape and moves toward the center of occlusal surface. It has a round appearance in horses between 10-15 years of age (13).

Galvayne's groove

Galvayne's groove is a longitudinal depression that appears on the labial aspect of the upper corner (I1) incisors (fig 4) and has also been considered as an useful criterion for aging horses by Galvayne (12) who reported that it first appears at the gingival margin at 10 years of age, extends about half way down the clinical crown at 15 years, comes into wear at 20 years of age and totally disappears by 30 years of age. However, Richardson et al (22) observed that Galvayne's groove extended three quarters of the length of the clinical crown in an 11 year old horse, yet extended down only half of the length of the clinical crown in a 20 years old horse.

Hook (Notch)

A hook, a localised overgrowth (fig 4), is often recognised at the caudolabial aspect of the occlusal surface of the upper corner incisor (I3) at any time after 6 years of age (21, 24). It is caused by incomplete occlusal contact between the upper corner incisor with its opposing lower tooth and is sometimes called a "seven year notch" because it was traditionally believed to appear at seven years of age (8, 13).

Canine teeth

Male horses normally have four canine teeth, two maxillary and two mandibular, that erupt at 4-6 years of age in the interdental space (21, 24). They are simple, pointed teeth with a caudal facing curve (figs 4 and 6). There is no occlusal contact between the upper and lower canines, with the upper ones being located more rostrally (2). Canine teeth are absent or are rudimentary in female horses (24). Rudimentary canine teeth were found to present in 48 out of 173 mares (27.8 %) by Colyer (7) and 3 out of 16 mares

(20 %) and 17 out of 22 male (77 %) by the present authors. Canine teeth can cause bit resentment in riding horses if they fail or are delayed to erupt or are dispositioned in the interdental spaces and need extraction. In order to extract a canine tooth an osteoplastic flap is created first over its lateral aspect in a horse with general anesthesia and then the tooth should only be withdrawn by a forceps when it is completely loosened. The flap should be sutured in place with simple interrupted fashion (17).

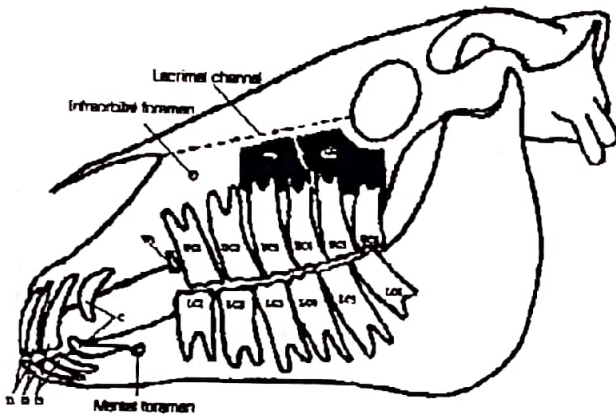


Figure 6: This diagram of the equine skull shows the lateral view of the incisors (I), canine (C), wolf teeth (Wt), and cheek teeth (CT) in a rostro-caudal order. The last four upper cheek teeth are located in the rostral sinus (RS) and caudal sinus (CS)

Molar and premolar teeth

One or both of the upper PM1 and less commonly, the lower PM1 can also be present as the small, vestigial 'wolf teeth' (fig 6) with a reported incidence of these teeth of 24.4% in females and 14.9% in males by Colyer (7), in both sexes, of 13% by Baker (4) and of 31.9% by Wafa (26) and 22.7 % in male and 6.25 % in female by the present authors. Normally, wolf teeth cause no problem. However, they can present clinically significant problem if they are delayed to erupt, misplaced or are excessively large (5, 14). Wolf teeth may be delayed in horses up to five years of age and may appear 1 and 3 cm rostral and lateral to their normal position (5). In these circumstances, wolf teeth may cause mucosal irritation or ulceration and interfere with the bit (5, 21). These misplaced or impacted wolf teeth can readily be corrected by

extracting with a root elevator or flathead screwdriver due to their relatively short roots (5). Sedation and local analgesia is required (21). The palatal artery is located immediately medial to the wolf teeth. Care should be taken not to damage it while extraction is being taken place, otherwise an embarrassing hemorrhage may follow. As the last three premolars (PM2, 3 and 4) and the 3 molars (M1, 2 and 3) are very similar in structure and appearance, they are all commonly termed as cheek teeth. An adult equine mouth normally contains 24 cheek teeth, forming four rows of 6 teeth that are accommodated in the maxillary and mandibular bones. Equine cheek teeth contain multiple cusps as shown in figs 7 and 8 (19). On transverse section, equine cheek teeth are rectangular shaped, except the first and last, i.e. PM2 and M3 which are somewhat triangular shaped (24). Cheek teeth possess long crowns, most of which is unerupted reserve crown that is embedded in the alveolus and gingiva (fig 8). At eruption, cheek teeth have no or relatively short true roots (enamel free), but these develop and elongate with age (fig 8). The upper cheek teeth have three roots and the lower cheek teeth (except M3 which has three roots) possess two roots, one rostral and one caudal (3, 24).

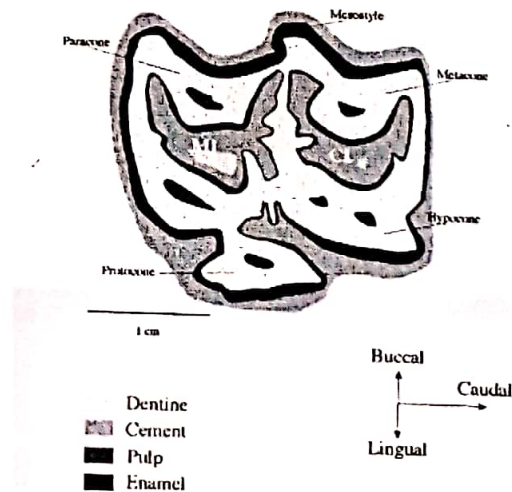


Figure 7: Transverse section of an upper PM4 showing dental cups. MI (mesial infundibulum), CI (caudal infundibulum), PE (peripheral enamel).

Dental eruption proceeds throughout the life of the equine tooth and normally growth rate corresponds with tooth wear (attrition). Dental wear in horses and zebras has been calculated as 2-3 mm per year (3, 10). Therefore, since all permanent teeth come into wear by 5 years of age, a horse's teeth should be fully worn by 30-35 years of age (3).

Both the maxillary and mandibular cheek teeth form a slightly curved row, with their concavity toward the

buccal and lingual aspect respectively (24). The cheek teeth are in very close contact at the occlusal surface even though their reserve crowns and roots greatly diverge. Pressure from the caudally facing first cheek teeth and the rostrally facing caudal cheek teeth compress the 6 cheek teeth together and along with the continuing deposition of coronal cement, maintains this tight occlusal contact throughout life in the normal horse (fig 6) (3, 9, 14).

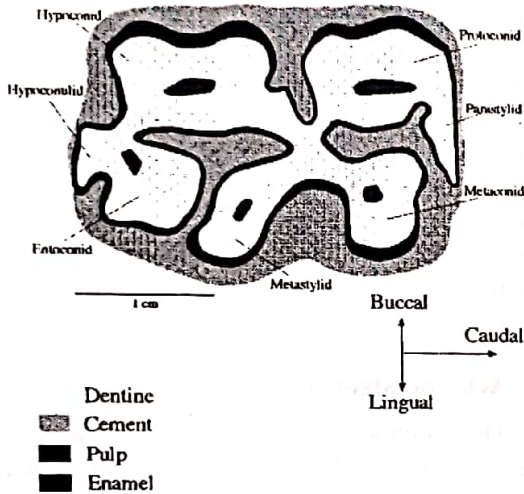


Figure 8: Transvers section of a lower PM4 showing dental cups.

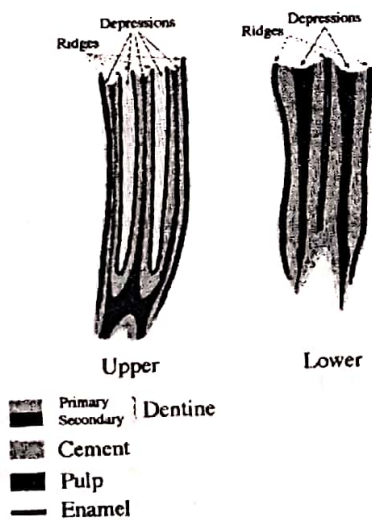


Figure 9: Appearance of ridges and depressions of the occlusal surface in vertical sections of upper and lower cheek teeth.

The caudal 3-4 cheek teeth are embedded in the rostral and caudal maxillary sinuses and in the young horse their large reserve crowns occupy a large part of these sinuses (fig 8). With age and eruption of reserve crowns, the residual sinus cavities increase in volume.

This intimate relation between the cheek teeth and sinuses can allow periapical infections of the caudal cheek teeth to cause maxillary sinus empyema.

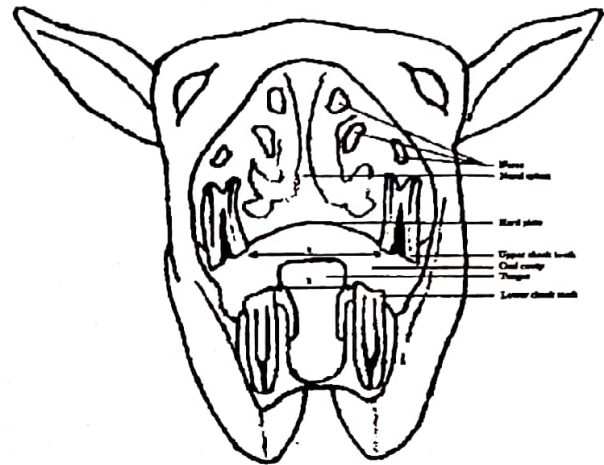


Figure 10: Vertical section of the horse head show that the distance between the dental arcs of the upper cheek teeth (a) is far bigger than that between the dental arcs of the lower cheek teeth (b) (a>b). Moreover, the width of the upper cheek teeth is greater than of the lower cheek teeth.

Equine cheek teeth enamel have a number of peripheral folds that extend the full crown length at the buccal, lingual, and the two interdental contact surfaces, with additional folds also present on the occlusal surface. The upper cheek teeth have two deep enamel invaginations termed the mesial (rostral) and caudal (distal) infundibula, which can vary from vase to funnel shape, depending on their vertical depths into the teeth. These infundibula extend for almost the full crown length and are usually incompletely filled with cement (fig 9) (3, 16, 24). The combination of wear resistant enamel with 2 adjacent softer dental tissues (cement and dentine) gives rise a number of ridges (styles) and depressions (grooves) on the occlusal surface (fig 4) (3). Each row of cheek teeth contains of a total of 10 ridges, two on the occlusal surface of each tooth, except the first and last which contain only one ridge (8). The ridges and grooves of the upper and lower cheek teeth interdigitate when the mouth is shut.

In normal horses the distance between the maxillary rows is approximately 30% wider than that between the mandibular rows, which is termed anisognathia (fig 10) (21). Additionally, the maxillary cheek teeth are wider than their lower counterparts. Consequently, when the mouth is closed, approximately one-third of the occlusal surface of the

upper cheek teeth are in contact with about half of the lower cheek teeth's occlusal surface. There are also differences between the maxillary and mandibular teeth in shape, number of pulp cavities and corresponding dental stars. The maxillary cheek teeth are squarer and have 5 pulp cavities in contrast to their lower counterparts which are more rectangular and contain 2 main pulp cavities with 5-6 subdivisions (figs 7 and 8) (17).

CONCLUSION

Adult equine mouths have four types of teeth, termed incisors, canines, premolars and molars, in a rostro-caudal order. Each type of tooth has certain morphological characteristics and specific functions. Equine incisor teeth contain certain wear related macroscopic features such as the incisal cup (cup), enamel spot (mark), dental star, hooks and Galvayne's groove that have also been traditionally utilised for estimating age with different degrees of reliability. Equine mouth occasionally contains small, vestigial 'wolf teeth' (PM1) and canine teeth which may occasionally cause bit resentment in riding horses due to delaying in eruption, misplacement or being excessively large and thus may need to be extracted in a horse with general anesthesia.

Equine cheek teeth form 4 arcades whose forming teeth are in close contact at the occlusal

surface. On the occlusal surface, individual tooth of an arcade contains ridges and depressions resulting from a very complex orientation of enamel folds and different wear resistant rates of cement, enamel and dentine. Consequently, compact or close approximations between teeth in a dental arcade associated with the presence of ridges and depressions of occlusal surface render cheek teeth an efficient grinding function. There are several factors, i.e. 1) ansognathia, 2) differences between cross sectional sizes of upper and lower cheek teeth and 3) slight buccal and lingual deviations of respectively the maxillary and mandibular teeth, that commonly predispose cheek teeth to various degrees of wear abnormalities. In addition, the maxillary cheek teeth contain a couple of infundibula incompletely filled by a commonly hypoplastic cement. This hypoplastic defects harbor decomposed food particles and microorganisms causing dental caries which prone the tooth to fracture which may result in even pulpitis, periapical diseases and sinusitis in advanced form.

Acknowledgment

The authors would like to thank to all managerial and technical staffs at the Sultansuyu Research and Breeding Institution for their kind helps durins carry ins out some of the study.

REFERENCES

1. Amand WB, Tinkelman CL. Oral disease in captive wild animals. In: Harvey CE, Editor. *Veterinary dentistry*. Philadelphia. Saunders 1985; 289-293.
2. American Association of Equine Practitioners. *Official guide for determining the age of the horse*, 5th ed. Colorado. Golden, 1988.
3. Baker GJ. Oral anatomy of the horse. In: Harvey CE, Editor. *Veterinary dentistry*. Philadelphia. Saunders, 1985; 203-216.
4. Baker GJ. A study of dental disease in the horse. PhD Thesis, Glasgow University, 1979.
5. Baker GJ. Diseases of the teeth. In: Colaham PT, Mayhew IG, Merritt AM, Moore JN, Editors. *Equine medicine and surgery vol 1*, 4th ed. Goleta. American Veterinary Publications Inc, 1991; 550-570.
6. Beeman, G.M. *Current therapy in equine medicine*, 2nd ed. Philadelphia. Saunders, 1987.
7. Colyer JF. Variations and diseases of teeth of horses. *Transactions of the Odontological Society of Great Britain (New Series)* 1906; 38: 47-74.
8. DeLahunta A, Habel RE. *Applied veterinary anatomy*. Philadelphia. Saunders, 1986.
9. Dixon PM, Copeland AN. The radiological appearance of mandibular cheek teeth in ponies of different ages. *Equine Vet Educ* 1993; 5: 317-323.
10. Dyce KM, Sack WO, Wensing CJG. *Textbook of veterinary anatomy*. Philadelphia. Saunders, 1987.
11. Eisenmenger E, Zetner K. *Veterinary dentistry*. Philadelphia. Lea & Febiger, 1985.
12. Galvayne S. *The XXth century book on the horse* 3rd ed. London. Bailliere, Tindall & Cox, 1912.
13. Goody PC. *Horse anatomy*. London. J. A. Allen & Company Ltd, 1983.
14. Hofmeyr CFB. Comparative dental radiology (with particular reference to caries and paradontal disease in the horse and the dog. *J South African Vet Med Assoc* 1960; 31: 471-481.

15. Kertesz P. A Colour atlas of veterinary dentistry and oral surgery. London. Wolfe Publishing, 1993.
16. Kılıç S. A light and electron microscopic study of calcified dental tissues in normal horses. The PhD thesis, Edinburgh University, 1995.
17. Lane JG. A review of dental disorder of the horse, their treatment and possible fresh approaches to management. Equine Vet Educ 1994; 6: 13-21.
18. McMullen WC. Equine Pract 1983; 5: 36.
19. Miles AEW, Grigson C. Colyer's variations and diseases of the teeth of animals. Cambridge. Cambridge University Press, 1990.
20. Miller WC, Robertson EDS. Practical animal husbandry 6th ed. London. Oliver and Boyd, 1952.
21. Mueller POE. Equine dental disorders: cause, diagnosis, and treatment. Compend Contin Educ 1991; 13: 1451-1460.
22. Richardson JD, Lane JG, Waldron KR. Is dentition an accurate indication of the age of a horse? Vet Rec 1994; 135: 31-34.
23. Richardson JD, Cripps PJ, Hillyer MH et al. An evaluation of the accuracy of aging horses by their dentition: A matter of experience? Vet Rec 1995; 137: 88-90.
24. St. Clair LE. Teeth. In: Getty R, Editor. Sisson and Grossman's the anatomy of the domestic animals vol 1, 5th ed. Philadelphia. Saunders, 1975; 460-470.
25. Tutt JFD. Veterinary notes for horse owners, 16th ed. London. Stanley Paul, 1968.
26. Wafa NSY. A study of dental disease in the horse. MVM Thesis, University College Dublin, 1988.
27. Walmsley JP. Some observations on the value of aging 5-7 year-old horses by examination of their incisor teeth. Equine Vet Educ 1993; 5: 195-298.