



CASE REPORT

F.U. Vet. J. Health Sci.
2020; 34 (2): 115 - 118
<http://www.fusabil.org>

A Fibrosarcoma Case with Poor Prognosis in a Golden Retriever Breed Dog

Murat TANRISEVER^{1, a}
Burak KARABULUT^{2, b}
Aydın ÇEVİK^{2, c}

¹ University of Firat,
Faculty of Veterinary,
Department of Surgery,
Elazığ, TURKEY

² University of Firat,
Faculty of Veterinary,
Department of Pathology,
Elazığ, TURKEY

^a ORCID: 0000-0003-3815-8543

^b ORCID: 0000-0002-4907-6159

^c ORCID: 0000-0001-6576-2151

A ten-year-old male, Golden Retriever breed dog was brought to the surgical clinic with a sign of swelling in the left pelvic region. The tumor suspected mass, located in the upper left of the pelvis, was totally excised. The mass of the tumor was approximately 1570 g and the size was 20x15x7 cm. Histopathological examination of the tumor revealed fibrosarcoma. Chemotherapy was initiated 1 week after the operation by using vincristine sulphate 3 times per week. Recurrence started again in the same region about two weeks after the last chemotherapy. Approximately 4 weeks later, the second surgical operation was performed because the mass grow up again. Patient died 8 hours after the last operation. In this case report, a case of fibrosarcoma with poor prognosis that did not respond to tumor surgery and chemotherapeutic treatment is presented.

Key Words: Dog, fibrosarcoma, histopathology

Golden Retriever Irkı Bir Köpekte Kötü Prognozlu Fibrosarkoma Olgusu

On yaşlı, erkek, Golden Retriever ırkı köpek, sol pelvik bölgede şişlik şikayetiyle cerrahi kliniğine getirildi. Sol-üst pelvis bölgesindeki tümör şüpheli kitle bütün olarak alındı. Kitlenin 1570 g ağırlığında ve 20x15x7 cm boyutlarında olduğu görüldü. Histopatolojik incelemede kitlenin fibrosarkoma olduğu tespit edildi. Kitlenin alınmasından 1 hafta sonra, haftada 3 doz vinkristin ile kemoterapiye başlandı. Aynı bölgede, tedaviden 2 hafta sonra tümörün tekrardan büyümeye başladığı görüldü. Yaklaşık 4 hafta sonra 2. cerrahi operasyon yapıldı, ancak hayvan operasyondan 8 saat sonra öldü. Bu vaka takdiminde, tümör cerrahisine ve kemoterapik tedaviye yanıt vermeyen kötü prognozlu bir fibrosarkoma olgusu sunulmuştur.

Anahtar Kelimeler: Köpek, fibrosarkoma, histopatoloji

Introduction

Fibrosarcoma is a malignant tumor that is usually seen in elderly dogs and originate from fibroblasts in connective tissue (1-3). Fibrosarcomas constitute approximately 6% of the dog skin and subcutaneous tumors (4). Golden Retrievers and Doberman Pinscher breeds have a genetic predisposition to fibrosarcoma. This tumor is more common in male dogs (5, 6). The aetiology of fibrosarcoma remains unclear. Although exposure to radiation is thought to be effective, trauma and underlying Paget's disease, fibrous dysplasia or chronic osteomyelitis are reported to be effective (7). The skin and subcutaneous tissues are the primary sites of occurrence of fibrosarcomas in dogs and other domestic animals (8, 9). It may develop in the skin, in the subcutaneous tissue of the thoracic cavity and extremities, in the oral and nasal cavity (3). Treatment in the veterinary literature has included surgery alone (10, 11), chemotherapy (12, 13), radiation therapy (14), or combination therapies (15). The aim of this case report was to evaluate the results of the combination of surgery and chemotherapy in this case.

Case Report

A 10-years-old male Golden Retriever dog was brought to Firat University Animal Hospital, surgery clinic with a skin swelling on the upper left side of the pelvis. After the clinical and radiographic examinations of the patient, certificate of approval was taken from animal owner and mass was removed surgically and biopsy samples were sent to the pathology department for histopathological and immunohistochemical evaluation. Chemotherapy was initiated 1 week after the operation by using vincristine sulphate 3 times per week. Tumor recurrence started again in the same region about two weeks after the last chemotherapy. Approximately 4 weeks later, the second surgical operation was performed when mass grow up again. Patient died 8 hours after the last operation.

Histopathological and Immunohistochemical Findings: The biopsy material macroscopically was white in color, elastic in structure, pieced, changing sizes and dimensions. Histopathological examination revealed, spindle shaped (fusiform), shifting, pleomorphic and anaplastic fibrocytes and fibroblasts in biopsy tissue (Figure 1-A). Histological features of tumor included spindle shaped cells, scant cytoplasm, elongated to oval shaped nucleoli, marked cellular pleomorphism and increase in cellular density. These cells also showed anisocytosis and anisonucleosis. Mitotic figures and multinucleated cells were also observed rarely (Figure 1-B). Cellular arrangement was herringbone pattern or interwoven arrangement to form eddies. The surrounding stromal

Received : 19.01.2020
Accepted : 06.05.2020

Correspondence Yazışma Adresi

Burak KARABULUT
University of Firat,
Faculty of Veterinary,
Department of Pathology,
Elazığ – TURKEY

bkarabulut@firat.edu.tr

tissue was, keloid-like or loose myxoid character. In addition, several small capillar veins were seen in the tumor stroma (Figure 1-C). Masson's trichrome staining also showed intense collagen tissue between the anaplastic fibrocytes and fibroblasts forming the tumor paranchyme (Figure 1-D). Since the surgical margins of the tumour are quite large (about 20 cm), each region could not examine in detail, so there was no clear information about whether the surgical borders were clean or not. Avidin-biotin complex (abc) method was used for immunohistochemical examinations with anti-S100 and anti-vimentin primer antibodies. Lymph node was used as positive control for S100 and vimentin antibodies. As negative control, these biopsy samples, without primary antibody application, were used. S100 positivity was found limited to the nuclei of fibrocytes and fibroblasts (Figure 1-E). It was seen that vimentin positivity was common and severe and that both the cytoplasm and the nuclei of the fibrocytes and fibroblasts were intensely stained (Figure 1-F). In the light of these findings, biopsy specimen was diagnosed as fibrosarcoma.

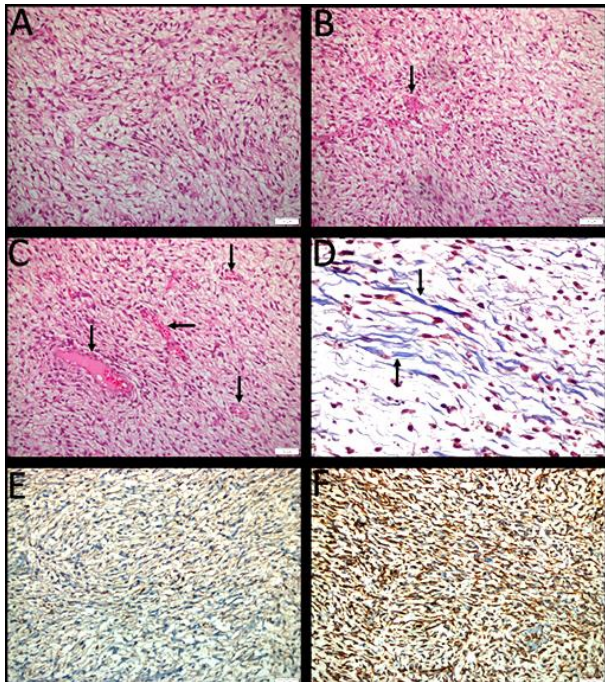


Figure 1. **A:** The general microscobic view of tumor tissue; shifting, pleomorphic and anaplastic fibrocytes and fibroblasts, H&E staining, 200X. **B:** Multi nucleated cell (arrow), H&E staining, 200X. **C:** Neovascularization of tumor tissue (arrows), H&E staining, 200X. **D:** Collagenous areas (arrows), Masson's trichrome staining, 400X. **E:** S100 positivity, immunoperoxidase staining, 200X. **F:** Vimentin positivity, immunoperoxidase staining, 200X

Surgical Procedure: The patient owner was informed about the dog's old age and the risk of recurrence of this malignant tumor. Preparations were made for the operation with the approval of the patient owner (Figure 2).

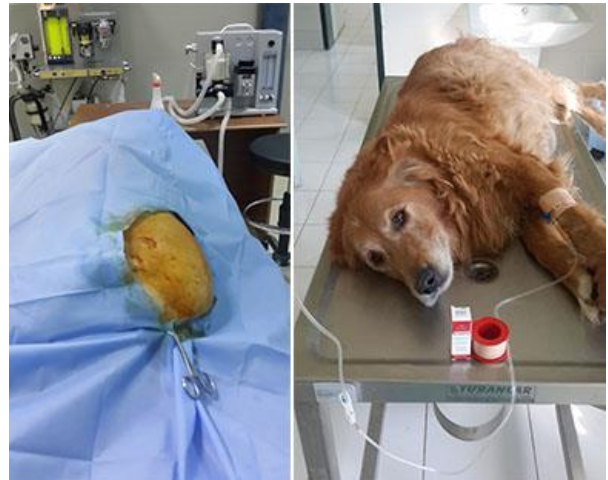

Figure 2. First operation and chemotherapy application

After general anesthesia of the patient, the skin was excised to reach the mass. Tumor mass was gelatinous and semi-fluid. All of the mass was removed from 2 separate incision lines and the skin was closed with sutures. The mass of the tumor was approximately 1570 g. and the size was 20x15x7 cm. One week after the operation, the chemotherapy application was started with using vincristine sulphate. Intravenous administration of vincristine sulphate (Vincristine, DBL®, Mayne Pharma PtyLtd, Melbourne, Australia) 0.025 mg/kg (0.5-0.7 mg/m², maximum 1 mg) in 500 mL isotonic serum with slow infusion at 3 times per week, but recurrence started in the same area and bilateral region about two weeks after the last chemotherapy. Approximately 4 weeks after the last chemotherapy, tumoral mass size was measured 31x21x9 cm (Figure 3 and 4).

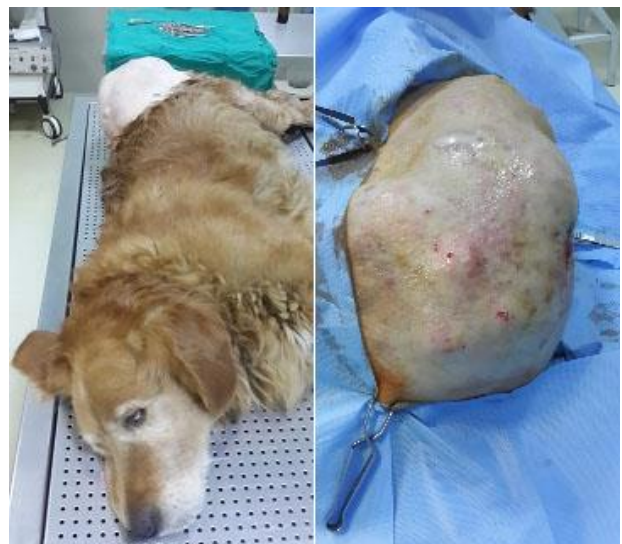

Figure 3. Recurrence of the fibrosarcoma

When it was decided for the second operation, low dosage anesthesia was used because of dog's age. In this operation wide and deep surgery was made. The extracted mass was weighed 3020 gr. During the operation, it was seen that there were milimetric protrusions covering the under the skin in one area. This skin part was removed and the wound line was closed with sutures. Parenteral antibiotic and nonsteroidal anti-inflammatory treatment was recommended for 5 days after the operation and the patient was discharged. The patient owner reported that the patient died 8 hours after the second operation. Because the animal owner didn't accept the necropsy, the reason of the death and metastasis could not be understood exactly.

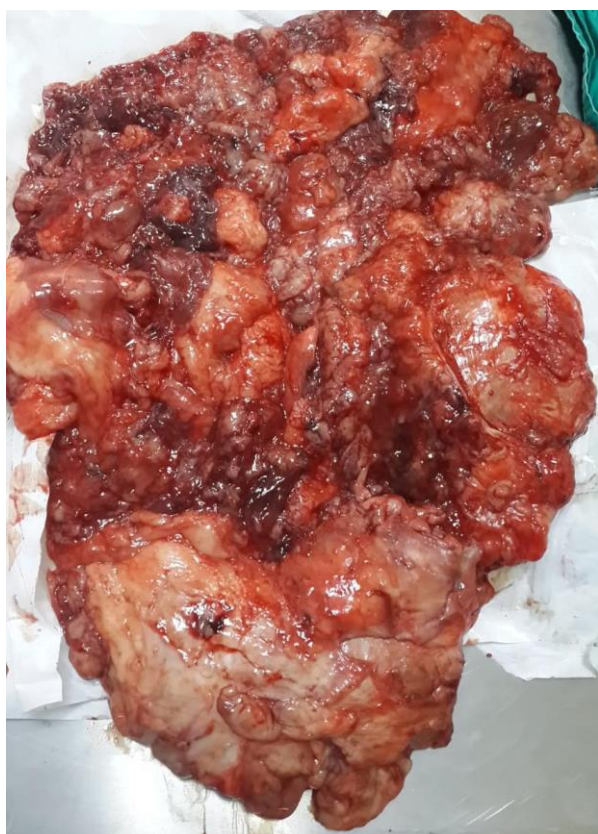

Figure 4. Removed tumoral mass

Discussion

Although radiation, chemotherapy and surgical excision treatments were reported to be safe and effective in the treatment of fibrosarcomas (3, 16), it was concluded that the desired result could not be obtained in this case due to the large size of the mass, poor prognosis and the age of the patient.

Prognosis of the tumor is dependent on histological grade, tumor size and adequate surgical treatment with tumor cells free margins (7). When the recovery rates of fibrosarcomas most commonly encountered in the oral cavity are examined, it is seen that radiotherapy provides high success in addition to surgical intervention. In these articles, it was found out that the size of tumors encountered in the related region does not exceed a few centimeters and radiotherapy applications are more effective in addition to surgical treatment (17, 18).

In the past, fibrosarcomas cases in dogs have been reported in the mouth (1, 19), extremities (20) vagina (21), and intestine (9) in Turkey. Histopathological and immunohistochemical findings obtained in these studies show similarities with our study. In one of these studies, euthanasia was performed because the tumor is located in the nasopharyngeal region (1), in others, especially the diagnosis of the tumor was emphasized and no information was given about chemotherapeutic (9) and surgical (19-21) treatment options.

It is suggested that the most effective treatment for dog soft tissue sarcoma is surgical excision. In general, bulky or measurable tumors have poor response to radiation therapy, and radiation therapy is the most efficacious for treating microscopic disease. The combination of surgery and chemotherapeutic treatment is seen as the most effective treatment method (22). In this case size of the tumor that 20x15x7 cm and 31x21x9 cm, it is thought that the death of the patient, after the second operation, may be related to the size of the tumor and the age of the patient.

In conclusion, this case of poor prognosis fibrosarcoma was evaluated clinically and histopathologically and it was reported that it might be useful to colleagues.

References

1. Atalan G, Atasever A, Yavuz Ü, Güneş V, Onmaz AC. Kangal Irkı bir köpekte oral fibrosarkom olgusu. *FÜ Sağ Bil Vet Derg* 2009; 23: 167-169.
2. Palmer N. Bones and Joint. In: Jubb KVF, Kennedy PC, Palmer N. (Editors). *Pathology of Domestic Animals*. Vol. 1, 4th Edition, London: Academic Press Inc 1993: 125-138.
3. Stannard AA, Pulley LT. Tumors of the skin and soft tissues. In: Moulton JE (Editor). *Tumors in Domestic Animals*. 2nd Edition, Berkeley: University of California Press 1978: 21.
4. Walder EJ, Gross TL. Neoplastic Diseases of the Skin. Part VI. Fibrocytic Tumors. In: Gross TL, Ihrke PJ, Walker EJ. (Editors). *Veterinary Dermatopathology*. St Louis: Mosby Year Book 1992: 407-418.
5. Ciekot PA, Powers BE, Withrow SJ, et al. Histologically lowgrade, yet biologically high-grade, fibrosarcomas of the mandible and maxilla in dogs: 25 cases (1982-1991). *J Am Vet Med Assoc* 1994; 204: 610-615.
6. Wallace J, Matthiesen DT, Patnaik AK Hemimaxillectomy for the treatment of oral tumors in 69 dogs. *Vet Surg* 1992; 21: 337-341.

7. Maliki O, Aleksandrov O, Carler P, et al. Fibrosarcoma of the nasal cavity: A case report. *EJENTAS* 2014; 15: 275-277.
8. Goldschmidt MH, Hendrick MJ. Tumors of the skin and soft tissues. In: Meuten DJ (Editor). *Tumors in Domestic Animals*. 4th Edition, Iowa: Iowa State University Press 2003: 45-117.
9. Avcı H, Yaygınül R, Gültekin M, et al. Primary intestinal fibrosarcoma caused by intestinal perforation in a dog: A case report. *Vet Med Czech* 2012; 57: 314-319.
10. Kuntz CA, Dernell WS, Powers BE, et al. Prognostic factors for surgical treatment of soft-tissue sarcomas in dogs: 75 cases (1986-1996). *J Am Vet Med Assoc* 1997; 211:1147-1151.
11. Bostock DE, Dye MT. Prognosis after surgical excision of canine fibrous connective tissue sarcomas. *Vet Pathol* 1980; 17: 581-588.
12. Moore AS. Recent advances in chemotherapy for nonlymphoid malignant neoplasms. *Compend Cont Educ Pract Vet* 1993; 15: 1039-1050.
13. Ogilvie GK, Obradovich JE, Elmslie RE, et al. Efficacy of mitoxantrone against various neoplasms in dogs. *J Am Vet Med Assoc* 1991; 198: 1618-1621.
14. McChesney SL, Withrow SJ, Gillette EL, et al. Radiotherapy of soft tissue sarcomas in dogs. *J Am Vet Med Assoc* 1989; 194: 60-63.
15. Forrest LJ, Chun R, Adams WM, Cooley AJ, Vail DM. Postoperative Radiotherapy for Canine Soft Tissue Sarcoma. *J Vet Intern Med* 2000; 14: 578-582.
16. Pirkey-Ehrhart N, Withrow SJ, Straw RC, et al. Primary rib tumors in 54 dogs. *J Am Anim Hosp Assoc* 1995; 31: 65-69.
17. Gardner H, Fidel J, Haldorson G, Dernell W, Wheeler B. Canine oral fibrosarcomas: A retrospective analysis of 65 cases (1998-2010). *Vet Comp Oncol* 2013; 1: 40-47.
18. Martano M, Iussich S, Morello E, Buracco P. Canine oral fibrosarcoma: Changes in prognosis over the last 30 years? *Vet J* 2018; 241: 1-7.
19. Atalay Vural S, Şahal M, Aydın Y. Bir köpekte ağızda fibrosarkom ve testislerde seminom olguları. *AÜ Vet Fak Derg* 1994; 41: 351-355.
20. Seyrek İntaş D, Rau FC, Michele U, Gerwing M, Kramer M. Köpeklerde Aksillar Bölgede Rastlanan Yumuşak Doku Kitlelerinin Tanısında Ultrasonografinin Önemi. *Türkiye Klinikleri J Vet Sci* 2014; 5: 91-96.
21. Bozkurt MF. Bir köpekte vaginal fibrosarkoma. *Kocatepe Vet J* 2013; 6: 83-86.
22. Ettinger SN. Principles of Treatment for Soft-Tissue Sarcomas in the Dog. *Clin Tech in Small Anim Pract* 2003; 18: 118-122.