

**Clinical *Eperythrozoon wenyoni* (Adler and Ellenbogen,1934) and *Haemobartonella bovis* (Donatin and Lestoquard,1934) Infection in A Cattle****Cem Ecmel ŞAKİ**
Edip ÖZERFırat Üniversitesi,
Veteriner Fakültesi,
Parazitoloji Anabilim Dalı,
Elazığ, TÜRKİYE

In a three years old Brown Swiss cattle showing the signs of fever, loss of appetite, exhaustion and anemia, blood smears stained with Giemsa was done. In the microscopic examination, round-shaped *Eperythrozoon wenyoni* on the surface of erythrocytes, in the numbers ranging from one to 50, a few chain-shaped *Haemobartonella bovis* on the peripher of erythrocytes and *Theileria sp.* were detected.

This study reports the presence of clinically *E. wenyoni* and *H. bovis* in cattle, for the first time in Turkey.

Key Words: Cattle, *Eperythrozoon*, *Haemobartonella*.

Bir Sığırdaki *Eperythrozoon wenyoni* (Adler ve Ellenbogen,1934) ve *Haemobartonella bovis*(Donatin ve Lestoquard,1934) Enfeksiyonu

İştahsızlık, halsizlik, yüksek ateş ve anemi semptomu gösteren 3 yaşında montefon bir ineğin giemsa ile boyalı kan frotileri yapıldı. Bunların mikroskopik muayenelerinde; eritrositlerin yüzeyinde, 1-50 adet arasında değişen sayıda yuvarlak şekilde *Eperythrozoon wenyoni*, eritrositlerin çevresinde zincir şeklinde *Haemobartonella bovis* ile birkaç tane *Theileria sp.* bulundu.

Türkiye'de klinik olarak yoğunlukla *E. wenyoni*, daha az yoğunlukta *H. bovis*'in görüldüğü hasta bir sığıra ilk kez rastlandığı bu çalışma ile ortaya kondu.

Anahtar Kelimeler: Sığır, *Eperythrozoon*, *Haemobartonella*.

Introduction

Eperythrozoon and *Haemobartonella* are rickettsial parasites of the family *Bartonellaceae*. The organisms are procaryotic forms occurring on the surface of erythrocytes. On Giemsa-stained blood smears, it appears as a pleomorphic coccoid or vesicular organism on the surface of the erythrocytes. Infections are common worldwide in cattle (2-4, 8).

Case Report

A three year old unhealthy Brown Swiss cattle showing the signs of fever (41,0 °C), loss of appetite and exhaustion was submitted from Bulanık/Muş in December 2002. These signs were observed nearly one month ago, and anemia was determined in the clinical inspection. In the microscopic examinations of blood smears stained with Giemsa; round-shaped *Eperythrozoon wenyoni*, in the numbers ranging from one to 50, was observed only on the surface of erythrocytes in highly-dense parasitemia, while chain-shaped *Haemobartonella bovis* was seen on the peripher of erythrocytes in less-dense parasitemia. In addition, a few *Theileria sp.* were detected in the microscopic examination.

In clinical examination, tick was not found on the animal and swelling was not present in lymph glands. Body temperature, heart frequency and respiration number were found 41.0 °C, 92 and 36 respectively. Ruminant movement was observed 5/5min. In examination of ruminal content, PH was 7.0, infuzoria amount was ++, in blood examination; RBC was found to be 2.0x10⁶/cu mm, MCV 76/cu µ and PCV 20%. Presence of anemia was revealed with these results. The microscopic examinations of blood smears dyed with Giemsa showed 1-50 items of round and roundish shaped *E. wenyoni* (Figure1) in dense parasitemia only on the surface of erythrocytes, chain shaped *H. bovis* (Figure 2) around erythrocytes in less dense parasitemia and a few *Theileria sp* in all the microscopic area.

The animal recovered within 3 days following oxytetracyclin application (three days, daily 10 mg/kg IM).

Geliş Tarihi : 05.02.2009
Kabul Tarihi : 08.03.2009**Yazışma Adresi**
Correspondence**Cem Ecmel ŞAKİ**Fırat Üniversitesi,
Veteriner Fakültesi,
Parazitoloji Anabilim Dalı,
Elazığ - TÜRKİYE**cesaki@hotmail.com**

Discussion

In the investigations (1-6, 8), clinical symptoms related to eperythrozoonosis and haemobartonellosis were shown. Although *E. wenyoni* was shown as the cause of anemia, it was stated that not anemia but only leucopenia was seen in the 2 cattle that factor was determined (7). This study reports the presence of clinically *E. wenyoni* and *H. bovis* in cattle, for the first time in Turkey.

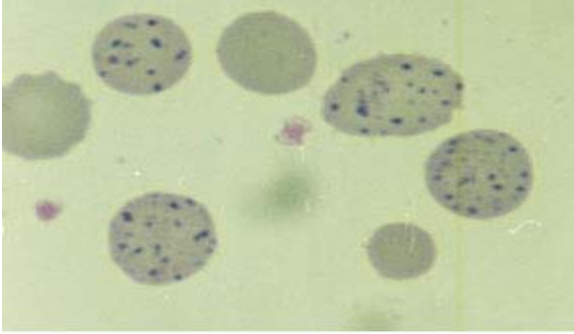


Figure 1. *Eperythrozoon wenyoni* x 236

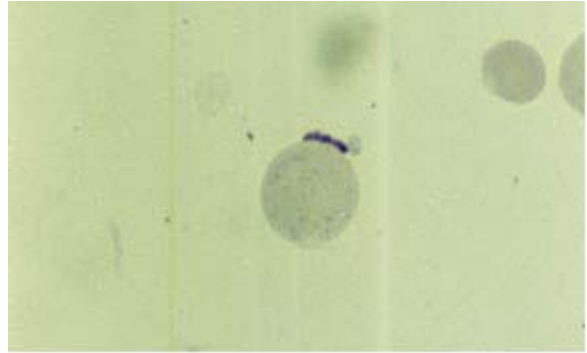


Figure 2. *Haemobartonella bovis* x 227

References

1. Brömel J, Zettl K. Die Eperythrozoonose Ein Bildbericht mit Literaturübersicht. *Praktische Tierarzt* 1985; 9: 689-698.
2. Fischer MS, Say RR. Tick Borne Diseases. *Manuel of Tropical Veterinary Parasitology*. Aberystwyth, UK: Cambrian Printers, 1989.
3. Gothe R, Kreier JP. Parasitic Protozoa. *Eperythrozoon and Haemobartonella*. J.P.Kreier (Editor). IV, New York: Academic Press, 1977; 263-294.
4. Kreier JP, Ristic M. Infectious Blood Diseases of Man and Animals Haemobartonellosis, Eperythrozoonosis,
5. *Grahamellosis and Ehrlichiosis*. W. Ristic (Editors). New York: Academic Press. 1963; 397-472.
6. Poole DB, Cutler RS, Kelly WR, Collins JD. *Eperythrozoon wenyoni* Anaemia in Cattle. *Vet Rec* 1976; 99(24): 481.
7. Purnell RE, Brocklesby DW, Young ER. *Eperythrozoon wenyoni* a Possible Cause of Anemia in British Cattle. *Vet Rec* 1976; 98: 411.
8. Quinlan JF. Scientific Letter. Suspected Eperythrozoonosis in Dairy Cows. *Iris Vet J* 1985; 39: 27.
9. Smith JA, Thrall MA, Smith JL, Salman MD, Ching SV, Collins JK. *Eperythrozoon wenyoni* Infection in Dairy Cattle. *JAVMA* 1990; 196(8): 1244-1250.